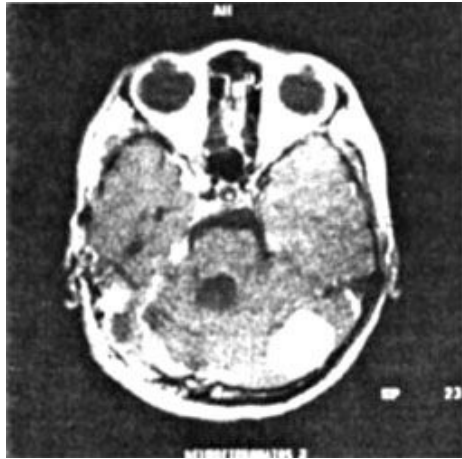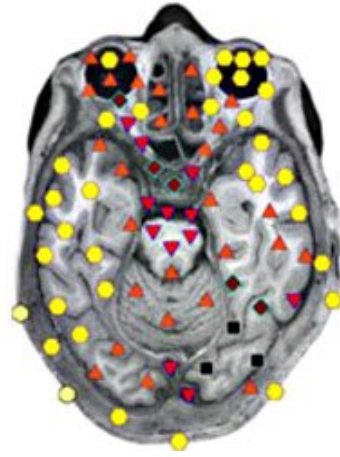




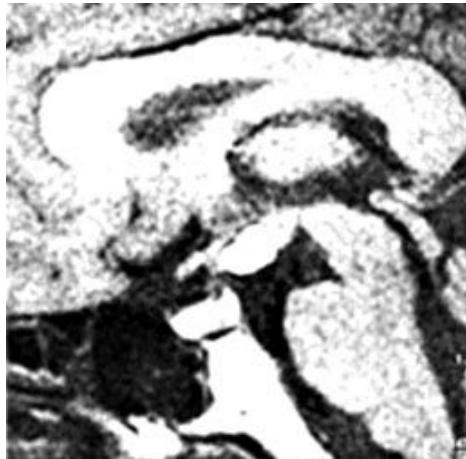Patient D., aged 57. Neurofibromatosis



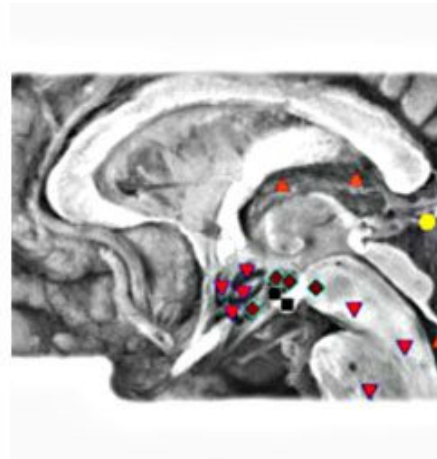
VS



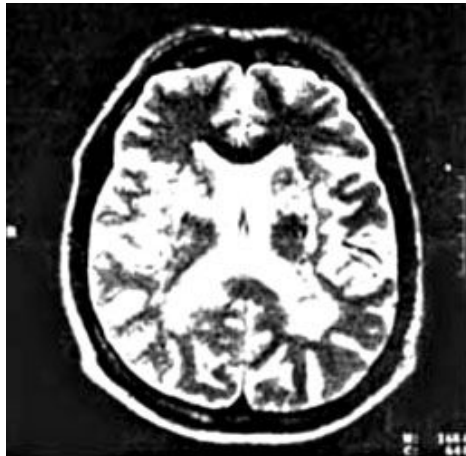Patient V., aged 37: Lymphoma of the hypothalamus



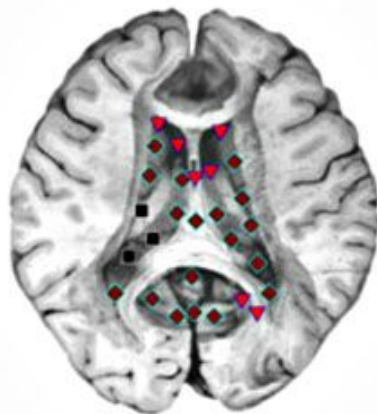
VS



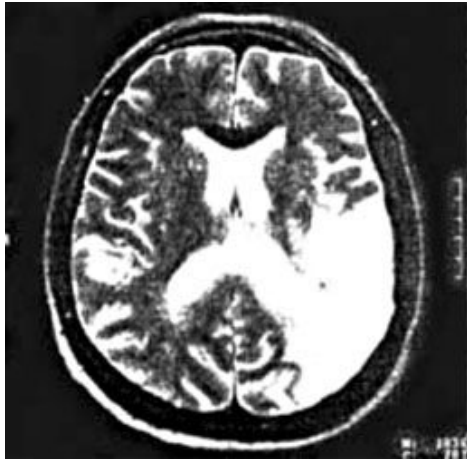Patient Z., 54 years old: Circulatory encephalopathy (chronic insufficiency of cerebral circulation)




VS



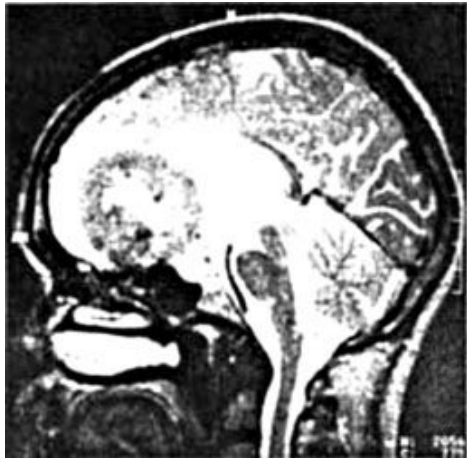Patient L., 43 years old: Acute ischemic stroke



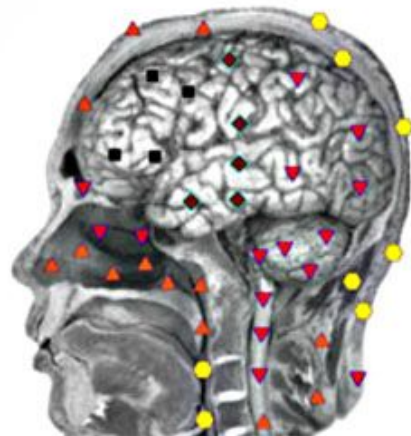
VS



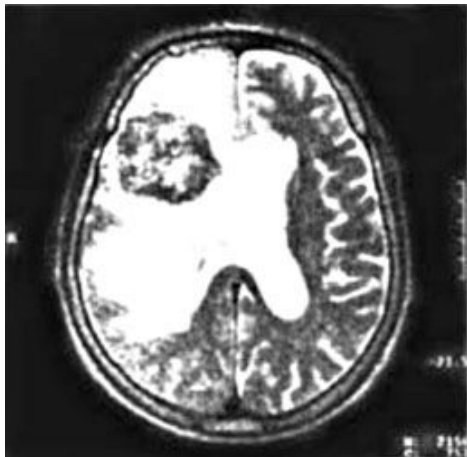Patient T., aged 38: Sub frontal meningioma



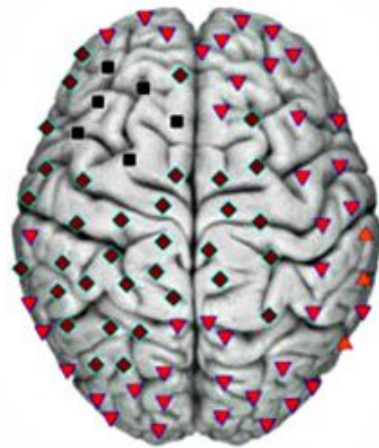
VS



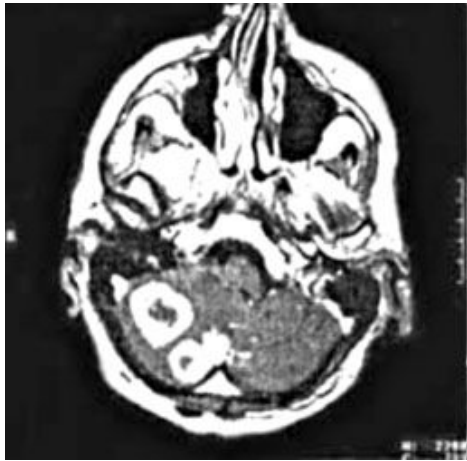
Patient S., aged 56: Metastasis of lung cancer in the left frontal lobe



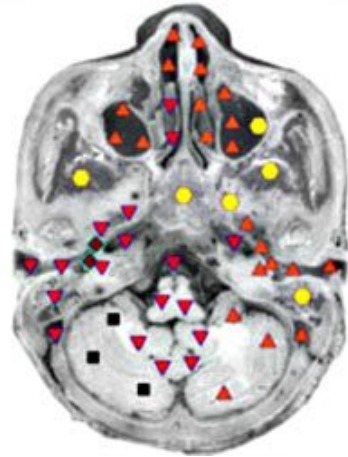
VS



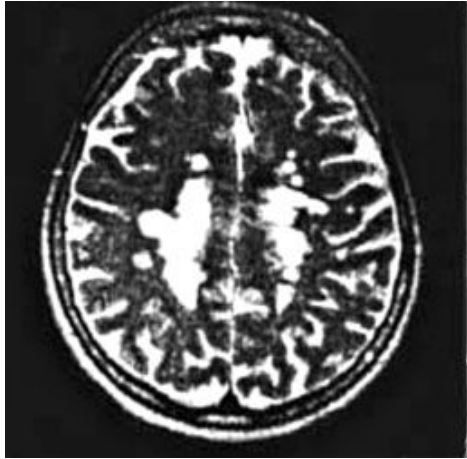
Patient Z., 62 years old: Metastases of adenocarcinoma of the kidney in the right hemisphere of the cerebellum



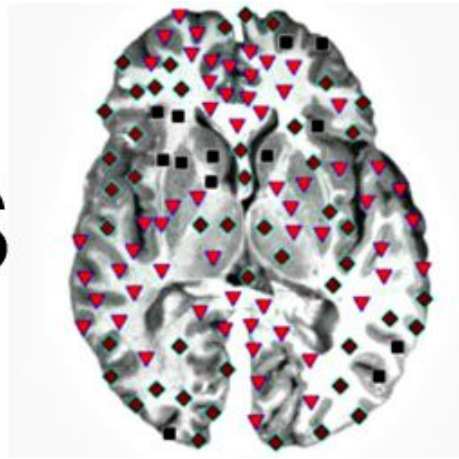
VS



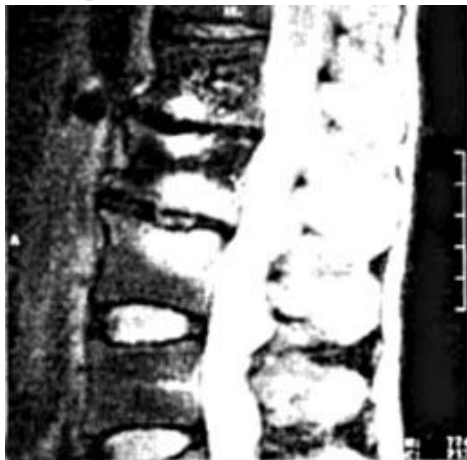Patient P., aged 47: Typical supratentorial foci in multiple sclerosis



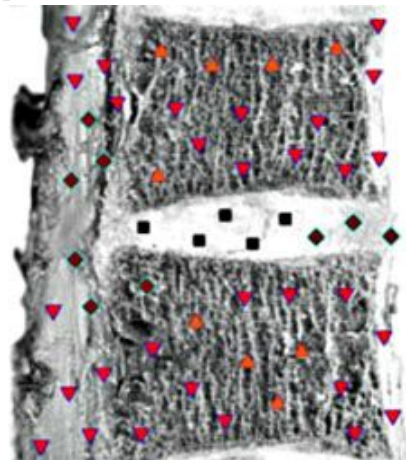
VS



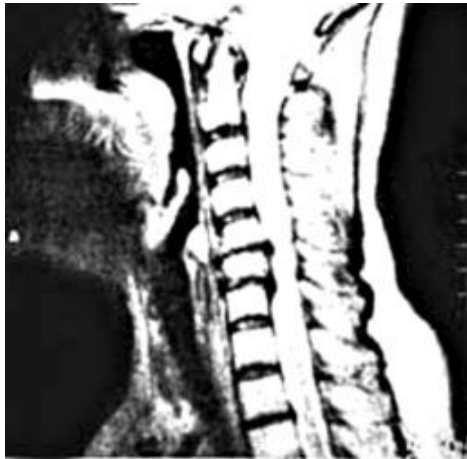E. The patient, 54 years old. Osteochondritis of the lumbar spine



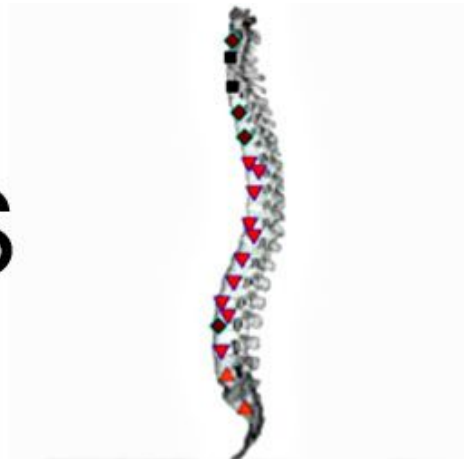VS



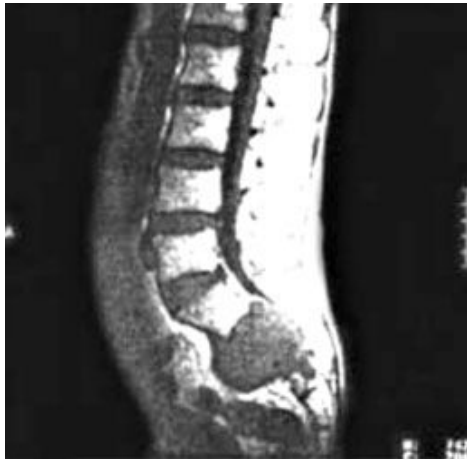Patient G., aged 56: Osteochondritis of the cervical spine with a reduction in the height of the rear discs and hernias



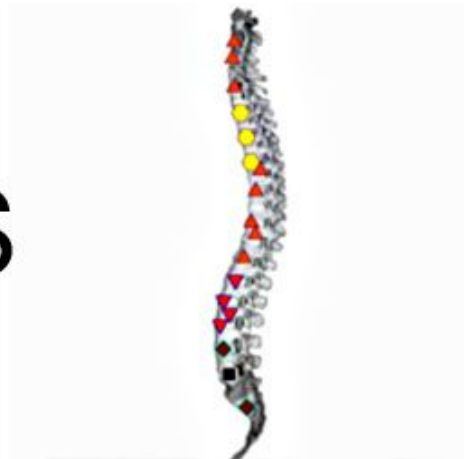VS



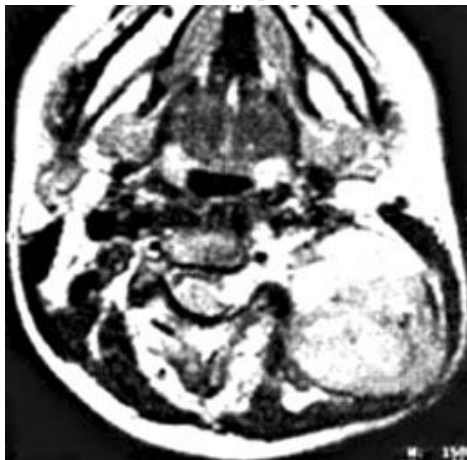Patient, 67 years old: Fibro sarcoma sacrum



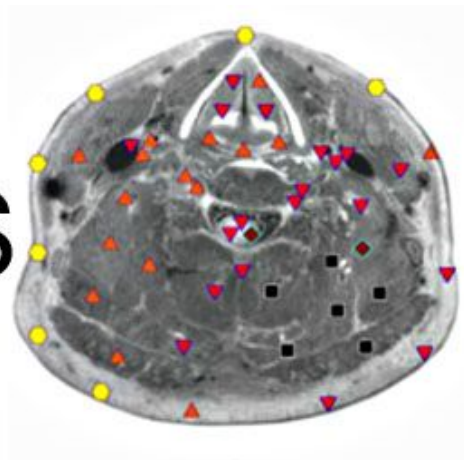
VS



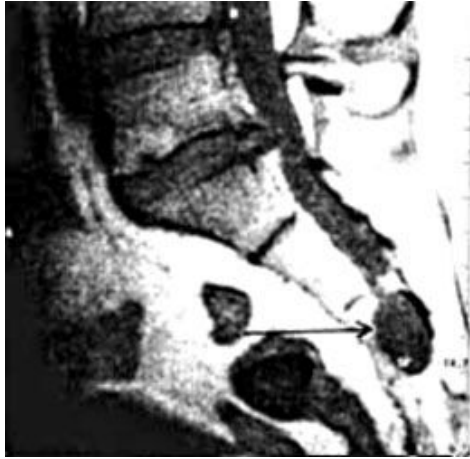Patient A., aged 58. hepatoblastoma neck localization



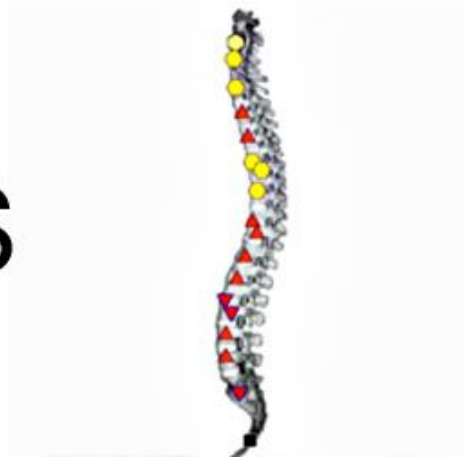
VS



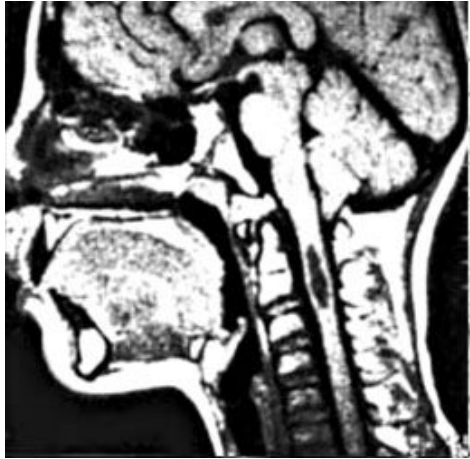Patient A., aged 58: hepatoblastoma neck localization



VS



Patient I., aged 49: Per neural arachnoid cyst



VS

